

The buccal frenum: Trends in diagnosis and indications for treatment of buccal-ties among 466 healthcare professionals

Richard Baxter¹  | Robyn Merkel-Walsh² | Lisa Lahey³ | Chad Knutsen⁴ | Soroush Zaghi⁴ 

¹Alabama Tongue-Tie Center, Pelham, Alabama, USA

²Diamond Myo, Ridgefield, New Jersey, USA

³Advanced Breastfeeding Care and Indy Myofunctional Therapy, Indianapolis, Indiana, USA

⁴The Breathe Institute, Los Angeles, California, USA

Correspondence

Richard Baxter, Alabama Tongue-Tie Center, 2480 Pelham Pkwy., Pelham, AL 35124, USA.

Email: info@TongueTieAL.com

Abstract

Background: The buccal frenum is connective tissue that adheres the mucosa of the cheek to the alveolar process. When restricted, this condition is commonly known as a buccal- or cheek-tie. Restrictive buccal frena are often treated during tongue- and lip-tie procedures, yet widely accepted classification, diagnostic and treatment guidelines are lacking.

Objective: Provide a scoping review on the evaluation and management of buccal-ties, including diagnosis, classification, symptoms and treatment, by surveying healthcare providers with experience evaluating and managing oral restrictions.

Methods: Literature review and IRB-approved survey to assess practice patterns among healthcare providers identified from online directories of tongue-tie release providers and associated allied health professionals.

Results: A multidisciplinary group of 466 providers responded. About 87% indicated that they assess buccal restrictions. Evaluation methods included finger sweep (89.1%), visual inspection (76.4%), tissue blanching (66.5%) and functional assessment (53.4%). Around 94% of providers reported that objective and subjective findings are both needed for diagnosis and that an estimated 5%–10% of infants may be affected. About 70% of providers release buccal-ties (if needed) simultaneously with tongue-ties, and 76.8% recommend post-operative stretches as necessary for optimal healing. Respondents indicated a need for further research, evidence-based assessments, a classification system and treatment protocols.

Conclusion: Evaluating a buccal frenum to diagnose a symptomatic buccal-tie relies upon visual inspection, palpation and assessment of oral function. Survey data and clinical experience are summarized to review classification systems, diagnostic/evaluation criteria and treatment recommendations as a foundational cornerstone for future works to build upon.

KEYWORDS

ankyloglossia, breastfeeding, lip-tie, tongue-tie

This is an open access article under the terms of the [Creative Commons Attribution](https://creativecommons.org/licenses/by/4.0/) License, which permits use, distribution and reproduction in any medium, provided the original work is properly cited.

© 2023 The Authors. *Journal of Oral Rehabilitation* published by John Wiley & Sons Ltd.

1 | BACKGROUND

The buccal frenum is a band of connective tissue located inside the mouth that adheres the mucosa of the buccal region of the oral cavity to the alveolar ridge of the maxillary and mandibular dental arches.¹ Buccal frena play a role in stabilizing the position of the lips and cheeks. When overly restrictive, the buccal frena can limit certain movements of the lips and cheeks during functions such as eating, speaking and smiling. In infants, for example, an excessively tight buccal frenum can restrict the opening of the mouth (gape) and latching on the breast leading to difficulty with breastfeeding. In other cases, restrictive buccal frena have been associated with limited mobility of the cheeks, feeding issues, weaknesses in cheek contraction for specific speech sounds and mastication, as well as difficulty brushing, gingival recession and even trouble with dentures.²⁻⁴ A restricted buccal frenum is commonly known as a buccal- or cheek-tie.

Recently, a resurgence in awareness and interest in restrictive oral frena, referred to as tethered oral tissues (TOTs) or lip-ties, tongue-ties and buccal-ties has led to increasing treatment rates among the general population.⁵ The reasons for the increase in diagnosis and treatment are not well understood, but likely an increase in social media awareness, increasing education of providers and renewed interest in breastfeeding have led to problem-solving strategies for mothers and babies. Despite the vast interest and debate on buccal frena, there is currently little to no peer-reviewed literature on assessment and treatment. Moreover, there are no widely accepted classification, diagnostic or standardized treatment guidelines based on scientific evidence available to date.

In an effort to better understand trends in practices among clinicians who routinely evaluate and treat this issue, we performed a wide-scope survey of healthcare providers with varying perspectives to highlight commonalities and differences. The aim of this study is to establish a foundation of understanding around the current standard of care and to use the collective multidisciplinary clinical expertise to develop research questions that can help to understand the condition and facilitate further research on this topic.

2 | METHODS

2.1 | Objective/Specific aims

To summarize and clarify definitions, diagnoses and indications for treatment of buccal-ties based on the best available evidence (limited published studies, provider experience and expert opinion).

2.2 | Study design

Survey of healthcare providers experienced in the evaluation of tongue, lip and buccal frena and management of restrictive tethered

oral tissues. IRB exemption was obtained from Solutions IRB, protocol 2023/06/3.

2.3 | Literature review

A systematic literature review was performed by assessing the MEDLINE database via PubMed for the key terms "buccal frenum," "buccal frenulum," "cheek tie," and "buccal tie." Articles referring to the maxillary labial frenum (lip-tie), periodontal surgery or not in English were excluded.

2.4 | Population surveyed

Invitations to participate in the survey were posted in 10 Facebook groups where thousands of surgical and therapeutic providers who assess and treat tongue-, lip- and buccal-ties gather to discuss cases relating to tethered oral tissues and functional sequelae.

2.5 | Survey instrument

A survey of current practices and provider opinions was undertaken. An 18-item questionnaire consisting of multiple-choice and open-ended questions was created to assess current practices and areas of need in research (Figure 1).

2.6 | Data collection and analysis

The data were collected using a HIPAA-compliant and confidential Google Form, then de-identified and analysed with Microsoft Excel and JMP 16.0 statistical software. Artificial intelligence (AI) was utilized to analyse the open-ended questions to identify key themes quantifiably and to synthesize the common research questions that were submitted via the survey. To eliminate the possibility of irrelevant or inaccurate data being included in or influencing the processing of the open-ended responses, all of the data processing was done within a private, sandboxed large language model (LLM) trained only upon the textual data of the survey responses. Statistics, word counts or percentages calculated by AI were reviewed and checked by the researchers for accuracy. AI was not used for manuscript creation.

3 | RESULTS

3.1 | Survey population

The survey population is composed of approximately 10000 individual healthcare professionals across various different Facebook groups. At least 3652 individuals saw the posts for the survey. We

Survey Instrument

1. Provider Type (choose the best answer):

- Dentist
- Physician
- Lactation Consultant
- Speech Therapist
- Occupational Therapist
- Myofunctional Therapist
- Bodyworker (PT, Chiropractor, Osteopath, CST)

2. Please indicate the primary ages you treat.

- Infants
- Children
- Adults
- A mix of Infants and Children
- A mix of Adults and Children
- All ages equally

3. How long have you been treating patients with oral restrictions (tongue-, lip- and buccal-ties)?

- 0-1 year
- 1-3 years
- 4-7 years
- 8-10 years
- Over 10 years

4. How many patients with oral restrictions do you help or treat each week?

- 0-5 patients a week
- 6-10 patients a week
- 11-15 patients a week
- 16-20 patients a week
- 21-30 patients a week
- More than 30 patients a week

5. When checking infants for tethered oral tissues, do you also check the buccal frena for restriction?

- Yes
- No

6. What percent of all infants do you think have restricted buccal frena (buccal-ties)?

- Less than 5%
- 5-10%
- 11-20%
- 21-30%
- 31-50%
- 51-75%
- Over 75%

7. Release Providers: What percent of tongue-tied infants do you also recommend to have buccal-ties treated? (Skip if not a release provider)

- 0%- Never
- 5%
- 10%
- 15%
- 20%
- 25%
- 25-50%
- More than 50% of the time

8. Release Providers: When you do release buccal-ties, is it typically: (Skip if not a release provider)

- At the same time as tongue or lip-tie release
- At a follow-up visit after tongue or lip-tie release
- Only if the parent comes back later with remaining issues
- I don't ever release buccal ties

9. What assessment techniques do you use to check for buccal-ties? (multiple choice)

- Visual inspection
- Palpation / Finger sweep for tension
- Pulling to check for blanching
- Assess for symptoms of buccal ties
- Other:

10. What clinical symptoms do you think are related to buccal-ties in infants?

- (Open Ended Response)

11. What clinical symptoms do you think are related to buccal-ties in children?

- (Open Ended Response)

12. What clinical symptoms do you think are related to buccal-ties in adults?

- (Open Ended Response)

13. The diagnosis of a buccal-tie:

- can always be achieved with physical exam findings alone.
- can always be achieved with assessment of symptoms alone
- always requires physical exam and assessment of symptoms.
- can sometimes achieve with physical exam findings alone.
- can sometimes achieve with assessment of symptoms alone.
- can sometimes achieve with either physical exam findings or assessment of symptoms alone.

14. Are stretches (wound-care, massages, etc.) needed for optimal healing after a buccal-tie release:

- Yes- Absolutely
- Sometimes can be helpful
- No- Not really necessary

15. I have seen patients improve clinically after a stand-alone buccal-tie release procedure. (They had lip and/or tongue-tie treated at another appointment, and had independent buccal-tie release with improvement.)

- No experience / N/A
- Strongly disagree
- Disagree
- Neutral
- Agree
- Strongly agree

16. What unanswered questions do you have or wonder about buccal-ties? What kind of research would you like to see on this topic?

- (Open Ended Response)

17. Do you have any ideas for buccal-tie research?

- (Open Ended Response)

18. Any additional comments on buccal-tie assessment, diagnosis, or treatment?

- (Open Ended Response)

FIGURE 1 Survey instrument. This 18-item survey instrument was distributed to providers worldwide via social media groups where experienced providers share cases and discuss treatment of restricted oral frena.

received completed survey responses from a sample of 466 professionals. The survey contact rate was 36.5%, the cooperation rate was 12.7% and the overall response rate was 4.66%.

The 466 responses to the survey were comprised of the following health professional disciplines: dentists (47.4%), speech-language pathologists (SLP) (17.8%), lactation consultants (IBCLC) (12.7%), registered dental hygienists (RDH) specializing in oro-facial myofunctional therapy (OMT) (10.3%), occupational therapists (OT) (4.7%), body professionals including physical therapists, chiropractors, osteopaths, craniosacral therapists (3.9%), physicians (2.4%) and midwives, nurse practitioners and physician assistants (0.86%). Respondents represented more than 15 different countries, including the United States, Canada, Denmark, Germany, Switzerland, Poland, England, Ireland, Australia, South Africa, Brazil, Argentina and the United Arab Emirates, among others.

The qualification of the surveyed providers in terms of years of experience in evaluating tongue-, lip- and buccal-ties was a median of 4–7 years: <1 year (7.9%), 1–3 years (23.8%), 4–7 years (36.9%), 8–10 years (14.8%) and >10 years (16.5%). The frequency with which the surveyed providers reported treating patients with oral restrictions is as follows: 0–5 patients/per week (39.7%), 6–10 patients/per week (30.4%), 11–15 patients/per week (10.7%), 16–20 patients/per week (6.9%), 21–30 patients/per week (7.1%) and >30 patients/per week (5.2%). The estimated mean number of cases evaluated per responder was 2800 ± 150 cases (mean \pm SEM, minimum 50, lower interquartile range 625, median 1250, upper interquartile range 3500, maximum >15 000). These values were used to rank the responders as novice (0–625 cases), intermediate (626–1250 cases), experienced (1251–3500 cases) and highly experienced specialists (>3500 cases). The various providers reported experience with all ages equally (19.1%), infants and children (35%), adults and children (12%), infants only (26.2%), children only (6%) or adults only (1.7%).

3.2 | Evaluation of buccal frenum

Overall, 87% of providers responded that they routinely assess their patients for buccal-ties when evaluating other tethered oral tissues such as tongue- and lip-tie. Highly experienced (94%), experienced (92%) and intermediate (89%) providers were much more likely than novice providers (77%) to routinely provide an evaluation of the buccal-ties ($p < .0001$; 20.3 Pearson chi-square, 3 degrees of freedom).

Regarding assessment techniques, there was near complete consensus that the most effective technique to assess buccal restrictions involves some form of palpation and finger sweep along the vestibule (89%); there were few novice providers in the sample who admitted not knowing how to assess (2.5%), relying on symptoms only (1.3%) or relying on visual indicators only (7.2%). Among those who endorsed palpation, 74% reported additional usefulness in pulling the cheek to look for blanching at the buccal frenum attachment site. Several providers recommended looking for cheek dimpling while sucking, gape, asymmetries or fascial tension in infants. Others

recommended looking for signs of periodontal recession or cavities (as a result of food pocketing), especially among children and adults.

There were many respondents (53.4%) who endorsed the importance of asking about symptoms before concluding on a diagnosis of a restrictive buccal frenum. Some providers reported they usually rely on the assessment and recommendation of the referring lactation consultant, body professional and functional feeding assessments. Novice providers were much more likely to rely on subjective symptoms to support their objective physical exam techniques in distinguishing between restrictive and non-restrictive buccal frena. The incidence of relying on symptoms was 57% for novice, 43% for intermediate, 39% for experienced and 24% for highly experienced providers ($p < .0001$; 12.8 Pearson chi-square, 3 degrees of freedom). Nevertheless, only 5.3% of providers expressed that buccal-ties can always be assessed based on physical exam findings alone, with 94% of providers expressing the importance of always assessing objective and subjective findings together. Less than one per cent of respondents expressed that buccal-ties could be diagnosed based on symptoms alone.

The respondents estimated that 5%–10% of infants may be affected by buccal-ties (median response); some providers estimated that restricted buccal frenum affects <5%, whereas others estimated >75% with a lower interquartile range of <5% and upper interquartile range of 21%–30%. Physicians, midwives, nurse practitioners and physician assistants were much more sceptical about the role, prevalence and impact of buccal-ties as compared to dentists, speech therapists, oro-facial myofunctional therapists, lactation consultants and body professionals based on their estimates of buccal-tie prevalence and indications for release ($p = .0047$, Pearson chi-square 69.6, 42 degrees of freedom).

3.3 | Clinical symptoms associated with restrictive buccal frena (Buccal-ties)

Potential clinical symptoms related to buccal-ties in infants included one or more of the following issues: poor latch, labial seal issues, aerophagia leading to gas, reflux and colic, milk spilling (anterior loss) during feeding, preventing flanging of the lips, fascial tension, poor gape or mouth opening. Many respondents noted that it is hard to distinguish between the impact of buccal versus lip and tongue restrictions. Some maintained that buccal-ties were rarely, if ever, associated with significant symptoms or functional implications.

When asked about clinical symptoms of buccal-ties in children, most noted feeding issues such as food pocketing, difficulty with straw drinking, poor saliva management and challenges with the prerequisite oral placement skill of lip rounding impacting the /u/, /o/ and /w/ sounds. Many also remarked that they see concerns with dental issues such as difficulty or pain with brushing the teeth, tooth decay, gingival recession and possibly poor maxillary growth. Some respondents noted issues with lip incompetence, mouth breathing and fascial tension. Many noted that they rarely release buccal-ties in children or reported they did not correlate buccal-ties with functional issues.

Regarding clinical symptoms for adults, responses were similar to children and included difficulty brushing the teeth and plaque retention, gingival recession, sinus issues, TMJ issues, denture retention issues, inability to blow or whistle, speech and feeding difficulties, food pocketing, fascial tension, limited mouth opening and a narrow smile. Many also reported that they do not examine or treat adults in their practice.

3.4 | Treatment of restrictive buccal frena (Buccal-ties)

Among the 230 release providers in the sample cohort, 70% of providers typically release buccal-ties at the same time as tongue- and lip-tie, if indicated; 4.3% choose to release the buccal-ties at a separate visit from tongue- and lip-tie procedures; 7% report that they only release the buccal frenum if there are remaining issues after initial treatment with tongue/lip-tie procedures; 18% reported that they never perform any procedures to release the buccal-ties.

Post-operative stretching protocols (wound care, massages, etc.) are often recommended for tongue-tie and lip-tie releases. The survey asked providers if stretches were needed for optimal healing after a buccal-tie release. The majority (76.8%) said 'yes, absolutely' stretches are needed after a buccal-tie release, 15.9% responded that stretches 'sometimes can be helpful' and 7.3% responded that stretches 'are not really necessary'. There were no statistically significant differences based on experience levels in these trends.

3.5 | Perception of outcomes after isolated release of buccal-ties

Providers were asked if they have personally seen patients improve clinically after a stand-alone buccal-tie release procedure, meaning the patient had a lip- and tongue-tie treated at another appointment and the patient had independent buccal-tie release with improvement. Among the $n=203$ providers with experience in this domain, 61.6% agreed or strongly agreed that they had personally seen clinical improvements after a stand-alone buccal-tie release procedure, 21.6% were unsure and 16.8% disagreed or strongly disagreed that there are benefits of isolated buccal-tie procedures.

3.6 | Research questions and needs

Responses included a need for standardization and criteria for determining if a release is needed, a grading or classification scale, assessment ideas and tools, if buccal-tie releases are needed at all, what symptoms they cause in various ages, the consequences of not releasing buccal-ties, does bodywork improve buccal-ties, does releasing them affect facial and dental growth, do they affect cheek dimples or make dimples go away.

3.7 | Additional comments

The majority wanted to learn more about the buccal frenum and the impact of buccal-ties, and they expressed that we need more research and clear guidance on assessment, grading, diagnosis, treatment and aftercare. Responses included a desire to promote a collaborative team approach to care. The authors were thanked for bringing this issue to light because there are many patients and providers asking questions highlighting this topic as an area of unmet research needs. Many also shared stories of their own buccal-tie release or a specific patient who saw improvements after only a buccal-tie release. Many physical therapists, chiropractors and osteopaths also reported a notable difference in fascial tension they could feel immediately after release. Some also mentioned that releases of buccal frena do not need to be done, are overtreated, and often cause more harm than good.

4 | DISCUSSION

The buccal frenum is a webbing of connective tissue located bilaterally in the vestibule of the maxillary and mandibular arches. This tissue has variable presentation and, in some cases, may be overly restricted in certain individuals. The term 'buccal-tie' describes a physically restrictive buccal frenum contributing to clinical symptoms.

The authors surveyed healthcare providers with experience evaluating and managing tethered oral tissues to build on the limited existing body of literature relating to buccal frena or buccal-ties. The literature review found a case report, cadaveric study, case series, survey and two review papers on this topic, as summarized below. The primary conclusion that can be drawn from these limited references is that more research is needed, especially concerning assessment guidelines, classification systems and indications for treatment. As such, this paper aims to evaluate the following questions: What is a buccal-tie? How does a provider assess the buccal frenum? What clinical symptoms can a restrictive buccal frenum influence? When is a release indicated? What does the collective experience of seasoned providers demonstrate? What are the current needs for future research?

4.1 | Systematic review

The authors identified around 75 papers via PubMed; 70 were unrelated and mainly referred to either periodontal surgery or the maxillary labial frenum, and 7 pertained to the actual buccal frenum or buccal-tie. A single case report of a patient with a maxillary denture that lost suction easily saw improvement after buccal-tie release.² A cadaveric study noted that the midline labial frenum comprises connective tissue alone, but the buccal frena contains connective tissue and muscle fibres.¹ An Australian provider detailed how most treated infants had lip and tongue-tie releases,

and 7 patients had lip, tongue and bilateral buccal-tie releases.³ In a follow up study, bottle-feeding infants underwent tongue- and lip-tie releases and saw improvements in reflux and feeding after the procedure, and 2 of these patients had lip-, tongue- and buccal-tie releases.⁶ Another mention of buccal-ties is the otolaryngologists' Clinical Consensus Statement: Ankyloglossia in Children which stated, 'Surgery to release a "buccal tie" should not be performed', with no support to back up this claim.⁷ They also state there are no criteria to date used to determine if buccal-tie release is needed.⁷ In August 2023, two additional papers were published mentioning buccal-tie. The first was a survey of parents who had tongue-, lip- or buccal-tie.⁸ The second was a systematic review on tongue-, lip- and cheek-tie that mentioned that 'additional investigation is strongly warranted' as cheek ties may impact breastfeeding, and standardized diagnostic criteria and a grading system are needed.⁹

4.2 | Assessment and diagnosis

In the survey results, 94% of providers agreed that diagnosing a buccal-tie required the assessment of objective (physical exam) and subjective findings (symptoms). There were 86.9% of providers surveyed who routinely assess their patients for buccal-ties. Experienced providers reported that the best methods for assessment of restricted buccal frena included palpation and a finger sweep in the vestibule (89.1%), visual inspection (76.4%), checking for blanching (66.5%) and assessing for symptoms (53.4%).

4.3 | Classification of attachment site

One of the most important aspects of buccal-tie treatment noted by respondents as well as the literature review was the need for a classification or grading system and assessment criteria. The Kotlow classification system for lip-ties is the most widely used and grades the maxillary labial frenum into four classifications, with Class 4 being the tightest.^{10,11} A later study by Santa Maria determined that a three-class rating scale would be more reproducible and reliable.¹² Santa Maria also stated that release should not be based on

appearance alone, which the results of the survey here also support. The proposed classification system for grading the appearance of a buccal frenum is as follows.

4.3.1 | Classification of buccal frenum attachment site (Figure 2)

- Class 1: Mucosal
- Class 2: Gingival
- Class 3: Alveolar ridge

This system is defined by the attachment site or insertion point of the frenum tension band to the maxillary or mandibular alveolar bone. A mucosal attachment (Class 1) would be the highest in the vestibule, an attachment to the gingiva (Class 2) would be in the middle of the alveolar bone and the alveolar ridge or Class 3 buccal frena would attach at or near the alveolar ridge. Insertion points closest to the ridge more commonly result in a higher degree of palpable tension and theoretically confer increased risk for the possibility of symptoms. However, the attachment site is only one factor to consider when evaluating the buccal frena for a diagnosis of buccal-tie. The acrostic BUCCAL can help providers determine several factors that could influence the decision to recommend treatment or wait and monitor the frenum. Does the tissue Blanch when examined? Is the tissue Uncomfortable for the patient when palpated? Is there a significant Clinical impact or symptoms consistent with buccal-ties? Are there Compensation patterns for the patient when sucking? Where is the Attachment site located? Are the cheeks experiencing a Limited range of motion due to the restrictive frenum? These questions are important to ask during an exam and will help the clinician determine whether or not the buccal frenum may be restrictive in that case.

4.4 | BUCCAL

- Blanching tissue
- Uncomfortable to palpate
- Clinical impact

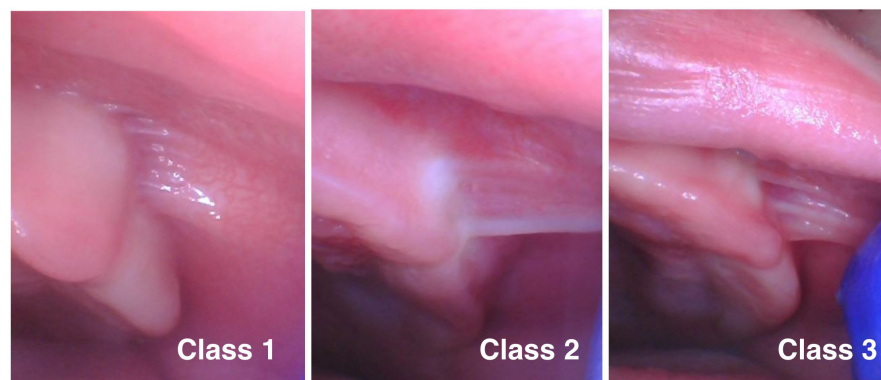


FIGURE 2 Classification of buccal frenum attachment site. Class 1: Mucosal attachment. Class 2: Gingival attachment. Class 3: Alveolar ridge attachment.

- Compensation patterns
- Attachment site
- Limited range of motion

4.4.1 | Symptoms

Reported symptoms related to buccal-ties in babies are thought to be related to labial seal issues, such as anterior loss of milk and aerophagia, which can lead to reflux, gas, colic and spit-up. A restricted buccal frenum could also lead to fascial tension, and releasing the tie could improve tension throughout the midface. For young children, a buccal-tie can lead to difficulty brushing their teeth, and adults can struggle with gingival recession.⁴ Food can pack in the area, increasing the risk of dental caries. Speech can also be impacted by limited buccal mobility to support labial rounding and protrusion to support the following sounds: /o/, /u/, /w/, /sh/, /ch/, /dz/ and /j/. In adults, fascial tension, gingival recession, food pocketing, denture retention, limited mouth opening and cosmetic concerns were reported. As with releasing a restricted tongue- or lip-tie, releasing a buccal restriction may help with current issues and may help prevent future issues, although treatment is advised for current issues only. With infant feeding problems, the tongue-tie is often deemed the most

important to release, the maxillary lip-tie is considered secondary and the maxillary buccal-ties are typically tertiary in importance based on the input among the respondents of this survey and the clinical experience of the authors.

4.4.2 | Treatment

Informed consent and discussing the risks and potential benefits are essential. The two main risks of the procedure are discomfort and reattachment. A minor risk includes the possibility of bleeding, and an extremely rare risk would be an infection. The maxillary buccal frena are often the most restricted. Very seldom, an aberrant mandibular buccal frenum will be restricted, and in those cases, care must be taken to avoid the mental nerve when releasing the buccal mandibular frenum, as this could risk temporary or permanent numbness. Tool selection should allow for excellent visualization during surgery, haemostasis, efficient cutting and a full release of restricted tissue. Many providers utilize dental lasers, such as a CO₂ laser, which allows for a quick procedure with minimal bleeding and excellent haemostasis. Examples of a CO₂ laser release in an infant (Figure 3) and a child (Figure 4) demonstrate a full release of restricted tissue, excellent haemostasis and minimal thermal damage.

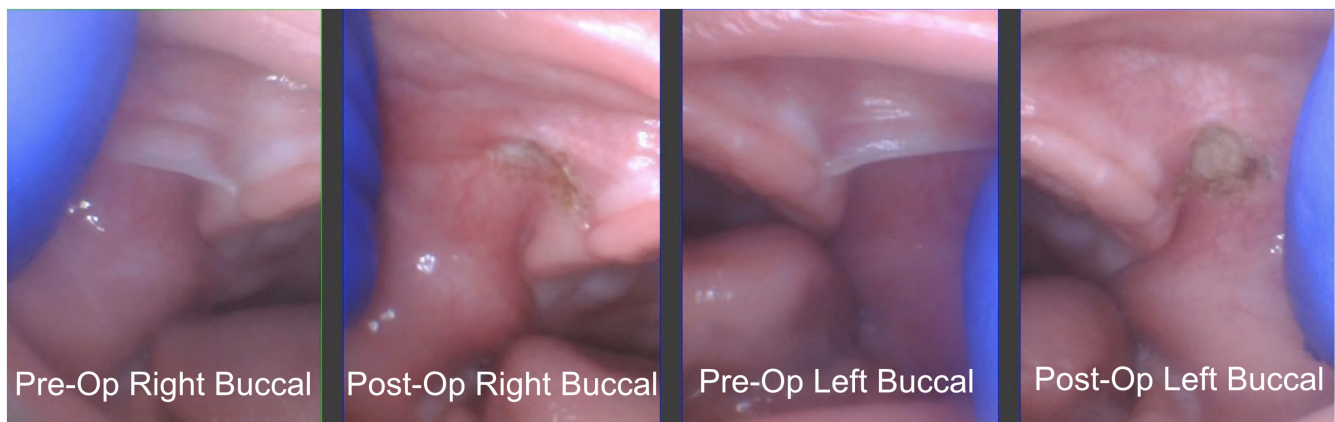
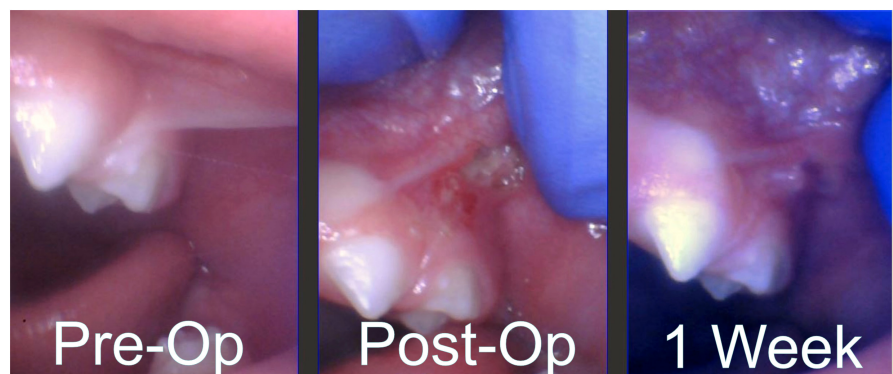

FIGURE 3 CO₂ laser release of restricted buccal frena in an infant. Before and after photos of treated bilateral restricted buccal frena demonstrate increased mobility of tissue, minimal thermal damage and excellent haemostasis.

FIGURE 4 CO₂ laser release of restricted buccal frenum in a child. In this photo, the left buccal-tie of a 2-year-old male was released with a CO₂ laser. The initial appearance of the restricted frenum, immediate post-op photo and 1-week healing photo are shown from left to right.



In this survey, 70.4% of providers reported they release the buccal frenum (if indicated) at the same time as lip and tongue-tie release; and, 92.7% of providers felt that stretches are absolutely necessary or at least sometimes helpful during the recovery period. Release providers prescribe postoperative stretches to prevent reattachment based on the principles of oral wound healing by secondary intention. Typical healing and stretching time is about 3–4 weeks in most cases, with most providers recommending 3–6x a day for stretches.

Many providers reported they do not treat buccal-ties, while others treated buccals in over 50% of tongue-tied infants. It appeared that more experienced providers were more inclined to routinely evaluate for and treat buccal-ties when indicated. Commonly, among those that do routinely treat buccal-ties, providers explained that bilateral treatment is preferred, as it could be beneficial to release both sides symmetrically to ensure a balance between the sides. Survey responses often mentioned fascial tension and strain, and suggested that treating only one side could potentially lead to an asymmetry or alter growth patterns.

For readers wishing to learn more about specific assessment, treatment and aftercare protocols, see [Appendix 1](#) for the infant assessment and treatment protocol and [Appendix 2](#) for the child and adult protocol.

4.5 | Limitations and research needs

These survey responses were provider opinions based on their own clinical experience, conversations with colleagues, social media or non-peer-reviewed websites.¹³ While clinical experience is certainly important and forms the basis for future research, more research is needed on this topic to aid clinical decision-making. In addition, the group sampled may or may not represent the entire population of providers and likely represents the most enthusiastic and interested in the topic.

Nevertheless, this study combining the clinical experience of many multidisciplinary providers, including release providers, lactation consultants, speech and feeding therapists and bodywork professionals, can give a starting point for current best practices where research does not yet exist. A few of the major needs mentioned in the open-ended questions were a need for a classification system, a discussion of likely symptoms and treatment recommendations. Further studies and clinical guidelines are needed. The authors hope that this article will serve as a foundational cornerstone for such future investigations.

5 | CONCLUSIONS

The evaluation of the buccal frenum to diagnose a buccal-tie relies upon visual inspection, palpation and assessment of oral function. Buccal-ties may affect aerophagia and feeding problems in

infants, oral hygiene and dental issues (caries, recession) in children and adults, speech issues, feeding issues and fascial concerns. Survey data and clinical experience are summarized to review classification systems, diagnostic/evaluation criteria and treatment recommendations as a foundational cornerstone for future works to build upon.

CONFLICT OF INTEREST STATEMENT

All authors declare no conflicts of interest to report.

PEER REVIEW

The peer review history for this article is available at <https://www.webofscience.com/api/gateway/wos/peer-review/10.1111/joor.13609>.

DATA AVAILABILITY STATEMENT

Data are not provided publicly but are available upon reasonable request.

ORCID

Richard Baxter  <https://orcid.org/0000-0002-7468-0040>

Soroush Zaghi  <https://orcid.org/0000-0002-3673-9099>

REFERENCES

- Iwanaga J, Takeuchi N, Oskouian RJ, Tubbs RS. Clinical anatomy of the frenulum of the oral vestibule. *Cureus*. 2017;9(6):e1410.
- Al Jabbari YS. Frenectomy for improvement of a problematic conventional maxillary complete denture in an elderly patient: a case report. *J Adv Prosthodont*. 2011;3(4):236-239.
- Hand P, Olivi G, Lajolo C, et al. Short lingual frenum in infants, children and adolescents. Part 1: breastfeeding and gastroesophageal reflux disease improvement after tethered oral tissues release. *Eur J Paediatr Dent*. 2020;21(4):309-317.
- Toker H, Ozdemir H. Gingival recession: epidemiology and risk indicators in a university dental hospital in Turkey. *Int J Dent Hyg*. 2009;7(2):115-120.
- Walsh J, Links A, Boss E, Tunkel D. Ankyloglossia and lingual frenotomy: national trends in inpatient diagnosis and management in the United States, 1997–2012. *Otolaryngol Head Neck Surg*. 2017;156(4):735-740.
- Hand P, Olivi G, Gioco G, Lajolo C. Bottle-feeding and gastroesophageal reflux disease improvement after restrictive tethered oral tissues release. *Eur J Paediatr Dent*. 2023. doi:10.23804/ejpd.2023.1817
- Messner AH, Walsh J, Rosenfeld RM, et al. Clinical consensus statement: ankyloglossia in children. *Otolaryngol Head Neck Surg*. 2020;162(5):597-611.
- Winkel T, Wilson J, Spence M, et al. Tethered oral tissue release among breastfed infants: maternal sources of information and treatment. *J Hum Lact*. 2023;39(3):505-514.
- Carnino JM, Walia AS, Lara FR, Mwaura AM, Levi JR. The effect of frenectomy for tongue-tie, lip-tie, or cheek-tie on breastfeeding outcomes: a systematic review of articles over time and suggestions for management. *Int J Pediatr Otorhinolaryngol*. 2023;171:111638.
- Kotlow LA. Oral diagnosis of abnormal frenum attachments in neonates and infants: evaluation and treatment of the maxillary and lingual frenum using the Erbium: YAG laser. *J Pediatr Dent Care*. 2004;10(3):11-14.

11. Kotlow LA. Diagnosing and understanding the maxillary lip-tie (superior labial, the maxillary labial frenum) as it relates to breastfeeding. *J Hum Lact*. 2013;29(4):458-464.
12. Santa Maria C, Aby J, Truong MT, Thakur Y, Rea S, Messner A. The superior labial frenulum in newborns: what is normal? *Glob Pediatr Health*. 2017;4:2333794X17718896.
13. Baxter R. What is a buccal tie or cheek tie? – Alabama Tongue-Tie Center. Accessed April 26, 2023. <https://tonguetieal.com/what-is-a-buccal-tie-cheek-tie/>

How to cite this article: Baxter R, Merkel-Walsh R, Lahey L, Knutsen C, Zaghi S. The buccal frenum: Trends in diagnosis and indications for treatment of buccal-ties among 466 healthcare professionals. *J Oral Rehabil*. 2023;00:1-11. doi:[10.1111/joor.13609](https://doi.org/10.1111/joor.13609)

APPENDIX 1

Examination and treatment protocol for infants

ASSESSING AND EVALUATING THE IMPACT OF RESTRICTED BUCCAL, LABIAL OR LINGUAL FRENA

Step 1: Assess oral structures and function

- Assess the tongue, lip, cheeks, palate and jaws for anatomical structures (form) and function (strength, range of motion, tone and coordination) through observation and palpation. Note feeding behaviours and biomechanics that may affect oral motor skills and feeding.
- Assess overall body tension and refer to body professional as needed.

Step 2: Identify common issues with buccal-ties

- Look for lack of lip flanging, proper seal, limited range of motion in cheeks during sucking, tight and thin upper lip and other buccal-tie-related signs.
- Note any leaking milk, nipple pain or other issues related to upper lip- and buccal-ties.
- Identify any additional feeding issues common with lip- and tongue-ties through a comprehensive history from the parent and using a complete symptom form.

Step 3: Assess cheeks and buccal frena

- Check for full and present buccal fat pads in cheeks.
- Assess the outside of cheeks for fullness and roundness.
- Ensure cheeks feel loose, soft and squishy during a range of motion assessment.
- Perform a finger sweep of the buccal vestibule to ensure smoothness and no hindrance (speed bump, fence).
- Assess lip and tongue mobility as well, as oral restrictions often co-occur.

Step 4: Engage functional professional

- Request a pre-frenectomy assessment of oral function by a qualified functional professional.
- IBCLCs, SLPs and OTs who specialize in feeding and oral function are trained to observe the impact of medical, postural, sensory, structural and functional oral skills needed for optimal feeding and oral development.
- Qualified functional professionals can help teach oral exercises, feeding positions and therapeutic strategies to optimize the infant's feeding ability.
- Functional professionals may inform the release provider about issues of concern and advocate for buccal-tie (or lip- or tongue-tie) release if needed.

Step 5: Pre-frenectomy exercises (if needed)

- Begin oral massage and oral motor exercises to release tension and help improve muscle tone near the buccal pads.
- Perform exercises like finger tapping, brushing the lips and cheeks, outward and inner massage of the buccal pads, etc., three to five times before feeding.

Step 6: Treatment

- Obtain informed consent, discuss risks, benefits and alternatives with parents.
- Adequate lighting and, ideally, magnification for visualization, restraint (swaddle) and support (assistant holding the head).
- Often performed with topical anaesthetic (consider 2% viscous lidocaine).
- Tool choice should allow for proper visualization, haemostasis, quick surgery time and a full, lay-flat diamond tissue release.
- Consider treating all ties simultaneously or in stages, depending on the situation.
- The maxillary buccal-ties are the most commonly restricted.
- Releasing all four buccal frena simultaneously with lip- and tongue-tie release (six wounds) may lead to a higher likelihood of discomfort and feeding trouble versus tongue- and lip-tie release alone (two wounds) or maxillary buccal-tie and lip- and tongue-tie release (four wounds).
- When in doubt, release lip- and/or tongue-tie first and release buccals later.
- Many providers release buccal-ties at no charge if also releasing a tongue and lip-tie.
- A minimal release of tissue (snip or clip) that is incomplete will likely yield few, if any, benefits to the patient for buccal, labial or lingual oral restrictions.

Step 7: Aftercare or wound care post-frenectomy

- The release provider must provide clear instructions for healing and feeding post-frenectomy.
- Oral frenectomy wounds typically require 3–4 weeks of stretches to prevent reattachment and to minimize the risk of a second procedure.

- Most providers recommend between 3 and 6x a day for stretches, but quality stretches with sufficient pressure and wound elongation are key.

Step 8: Follow up by functional professional and release provider

- Follow up at 1 week, either in-person or via photo, is critical to ensure success, to change technique if needed and to provide a deeper stretch if sites are beginning to reattach.
- Assess feeding, form and function post-frenectomy.
- Teach new latch and positioning techniques for both breast and bottle-feeding as needed with new suck patterns and increased mobility.

Note:

- This protocol should be tailored to individual needs and performed by trained professionals in a multidisciplinary team.

APPENDIX 2

Examination and treatment protocol for children and adults

ASSESSING AND EVALUATING THE IMPACT OF RESTRICTED BUCCAL, LABIAL OR LINGUAL FRENA

Step 1: Assess oral structures and function

- Assess the tongue, lip, cheeks, palate and jaws for anatomical structures (form) and function (strength, range of motion, tone, and coordination) through observation and palpation. Note feeding behaviours and biomechanics that may affect oral motor skills and feeding.
- Assess overall body tension and refer to body professional as needed.

Step 2: Identify common issues with buccal-ties

- Check for an unresolved buccal fat pad (fatty sucking pad).
- Assess for compensatory strain in the muscles of the cheeks and lips (jaw jutting, retraction of the lower lip or tongue protrusion).
- Note asymmetry while performing oral motor tasks.
- Assess the ability to contract the cheeks and round or protrude the lips for /o/, /u/, /w/, /tʃ/, /ʃ/, /r/, /dʒ/ and /z/.
- Analyse the contraction in the cheeks to support chewing, stabilizing a bolus and swallowing.
- Note any pocketing of a bolus in the lateral sulci.
- Look for cheek activation during mastication.
- Note decreased suctioning in the cheeks when stabilizing a solid on the chewing surface.
- Identify any additional feeding issues common with lip- and tongue-ties through a comprehensive history from the parent and using a complete symptom form.

Step 3: Assess cheeks and buccal frena

- Perform a finger sweep of the buccal vestibule to ensure smoothness and no hindrance (no speed bump or fence).

- Pull cheek laterally to visually check for tissue blanching and location of attachment.
- Assess lip and tongue mobility as well, as oral restrictions often co-occur. Beware of compensations like floor of mouth elevation that can hide posterior tongue restriction.

Step 4: Engage functional professional

- Request a pre-frenectomy assessment of oral function by a qualified functional professional including SLPs who have postgraduate training in feeding and oro-facial myofunctional therapy, RDHs who are trained in oro-facial myofunctional therapy, and OTs who have postgraduate training in oral motor and feeding.
- These professionals observe the impact of postural, sensory, structural and functional oral skills needed for optimal feeding, speech, oral rest habits and oral development.
- Qualified functional professionals can help teach oral exercises, and therapeutic strategies to optimize the child or adult's oral function depending on their scope of practice.
- Functional professionals may inform the release provider about issues of concern and advocate for buccal-tie (or lip- or tongue-tie) release if needed.

Step 5: Pre-frenectomy exercises

- Begin oral motor or oro-facial myofunctional exercises to prepare the child or adult for release and to help improve muscle tone and coordination.
- Acclimate the patient with oral motor sensory tools, exercises and intraoral stimulation
- Train caregivers on expectations and how to properly execute therapeutic tasks.

Step 6: Treatment

- Obtain informed consent, discuss risks, benefits and alternatives with parents.
- Adequate lighting and, ideally, magnification for visualization and support (assistant holding the head, parents holding hands, mouth prop if needed).
- Anaesthetic is critical (consider compounded topical and injected 2% lidocaine).
- Tool choice should allow for proper visualization, haemostasis, quick surgery time and a full, lay-flat diamond tissue release of any restricted areas.
- Consider treating all ties simultaneously or in stages, depending on the situation.
- The maxillary buccal-ties are the most commonly restricted.
- Releasing all four buccal frena simultaneously with lip- and tongue-tie release (six wounds) may lead to a higher likelihood of discomfort and feeding trouble versus tongue- and lip-tie release alone (two wounds) or maxillary buccal-tie and lip- and tongue-tie release (four wounds).
- When in doubt, release lip- and/or tongue-tie first and release buccals later.

- Many providers release buccal-ties at no charge if also releasing a tongue and lip-tie.
- A minimal release of tissue (snip or clip) that is incomplete will likely yield few, if any, benefits to the patient for buccal, labial or lingual oral restrictions.

Step 7: Aftercare or wound care post-frenectomy

- The release provider must provide clear instructions for healing and feeding post-frenectomy.
- Functional professional prescribes targeted individualized oral motor/oro-facial myofunctional exercises.
- Oral frenectomy wounds typically require 3–4 weeks of stretches to prevent reattachment and to minimize the risk of a second procedure.
- Most providers recommend between 3 and 6x a day for stretches, but quality stretches with sufficient pressure and wound elongation are key.

Step 8: Follow up by functional professional and release provider

- Follow up at 1 week, either in-person or via photo, is critical to ensure success, to change technique if needed and to provide a deeper stretch if sites are beginning to reattach.
- Assess feeding, speech, form and function post-frenectomy.
- Teach new oral rest posture, nasal breathing and swallowing patterns, as needed.

Note:

- This protocol should be tailored to individual needs and performed by trained professionals in a multidisciplinary team.