

Bottle-feeding and gastroesophageal reflux disease improvement after restrictive tethered oral tissues release



P.Hand, G.Olivi, G.Gioco, C.Lajolo

Head and Neck Department, "Fondazione Policlinico Universitario A. Gemelli – IRCCS". School of Dentistry, Università Cattolica del Sacro Cuore, Rome.

e-mail: philip@aestheticlaserdentistry.com.au

DOI 10.23804/ejpd.2023.1817

Abstract

Aim This study aimed to determine the impact of laser surgical tongue-tie, lip-tie, buccal-tie release on bottle-feeding and gastroesophageal reflux disease (GERD) after functional assessment of tongue and lip movement in a prospective cohort study conducted from June 2019 to June 2020 in a private general dental practice.

Methods Preoperative, one-week and one-month postoperative surveys were completed, using the Revised Infant Gastroesophageal Reflux Questionnaire (I-GERQ-R). All study participants were bottle-feeding dyads (0–12 weeks of age) with untreated ankyloglossia and/or tethered maxillary/buccal frena.

Results The study had 40 bottle feeding infants enrolled. Posterior tongue-tie was noted in 67.5% of this cohort. Statistically significant improvement in I-GERQ-R scores was reported between preoperative (16.6, SD: 6.1; min-max: 8-28), 1 week (14.1, SD: 4.2; min-max: 6-24) and 1 month I-GERQ-R total scores (9.1, SD: 4.5; min-max:3-27) (ANOVA test - $P < .001$).

Conclusion: This study confirms the need for functional assessment of tongue and lip movement for this significantly affected cohort when surgical release is proposed. Laser surgical release (frenotomy) of tongue-tie, lip-tie, buccal-tie resulted in significant improvement in I-GERQ-R outcomes were found for cohorts of the classically recognised anterior tongue-tie and the less obvious (without functional assessment) and less diagnosed posterior tongue tie were found.

Background

The effects of tongue tie in the newborn on breastfeeding success has been well researched over many decades. Effects on maternal discomfort, infant weight gain [Puapornpong et al., 2016], air induced reflux [Siegel, 2016] and orofacial growth retardation [Pompeia et al., 2017] have been noted. Lip-tie and buccal-tie are considered by a growing number of researchers

KEYWORDS Bottle-feeding, laser frenotomy, gastroesophageal reflux, ankyloglossia, posterior tongue-tie, lip-tie, buccal-tie.

to also play a part in these feeding difficulties but the research for this is still sparse.

If health professionals fail to diagnose a short lingual frenum, the correlated impairment can lead to a cascade of several malfunctions, that starts in children with atypical swallowing, may lead to oral breathing and craniofacial growth impairment [Huang et al., 2015; Vaz and Bai, 2015] and may also lead to speech impediment and sleep disorder during childhood and adolescence. During the life these alterations can be associated or cause other oral and/or general health problems, including postural modification [Olivi et al., 2012].

Early detection and surgical intervention in newborns and infants may prevent this cascade of functional impairments from happening. All of us are born with oral frenums (tethered oral tissues). Whether these tethered oral tissues are restrictive is the issue, and when the mother has been assessed appropriately and other conservative measures are not proving beneficial, there are many breastfeeding dyads that can, and should be benefitted by surgical intervention [O'Callaghan et al., 2013; Pransky et al., 2015; Ghaheri et al., 2017; Caloway et al., 2019]. This may be achieved by lingual frenotomy, with or without labial frenotomy and/or buccal frenotomy, and depends upon a well diagnosed need for such intervention. This study as part of a series of investigations looks into whether bottle-fed infants can also benefit from such intervention. A previous investigation where the cohort was breastfeeding infants, looked at surgical release of restrictive tethered oral tissues (TOTS) in infants to improve breastfeeding and gastroesophageal reflux disease (GERD) [Hand et al., 2020].

Introduction

Breastfeeding is recognised as the optimum nutrition for infants and is beneficial for mothers and infants' health. These

guidelines are based upon numerous studies that have identified the protective nutritional and health benefits of breastfeeding [Victora et al., 2016].

The current National Health and Medical Research Council infant-feeding guidelines in Australia follows the WHO guidelines and recommends exclusive breastfeeding for infants up to around 6 months of age, and that breast-feeding should be continued until 12 months of age and beyond, for as long as the mother and child desire [Infant Feeding Guidelines. National Health and Medical Research Council: Canberra, 2012., 2012]. The WHO reaffirmed this in 2018 in the Infant and Young Child Feeding resolution WHA 71.9. [WHO, 2018].

Although the percentage of Australian mothers who initiate breastfeeding has increased during the past few decades [Amir and Donath, 2008], it is well known that guidelines regarding the duration of breastfeeding are not followed by many women, for a wide variety of reasons [Colin and Scott, 2002].

WHO figures worldwide show that 63% of women have stopped solely breastfeeding by 6 months of age [Victora et al., 2016]. Moreover, only 15% of mothers had exclusively breast-fed their infant to around 6 months of age, in line with Australian National Health and Medical Research Council guidelines [Australian Institute of Health and Welfare 2011, 2011].

Despite the World Health Organization (WHO) recommendations for exclusive breastfeeding (EBF) for the first 6 months of life (www.who.int), the United States of America's Center for Disease Control (CDC)'s most recent report states only 24.9% of mothers reach this goal.

As a consequence, the vast majority of infants are bottle-fed prior to 6 months of age, either with expressed breastmilk, infant formula, or a combination of the two.

Consensus in the literature and from clinical experience suggests that babies with limited tongue mobility due to ankyloglossia can have a shallow latch and poor oral seal around the nipple [Walsh and McKenna Benoit, 2019]. It seems reasonable to postulate that this is also applicable to the teat of a bottle.

Several studies reported that ankyloglossia (either classic anterior tongue-tie or posterior restriction) [Geddes et al., 2008] and a tethered maxillary labial frenum (upper lip tie) cause altered latch and sucking mechanics [Ghaheer et al., 2017].

There are a wide variety of documented treatment options for breastfeeding difficulties in infants. Amongst these options are using a nipple shield, change in breastfeeding technique and position, chiropractic care [Fry, 2014], craniosacral therapy or osteopathic care [Kaiser et al., 2020]. All of these treatment

options have been seen as beneficial to improve breastfeeding outcomes with suspected ankyloglossia [Walsh and McKenna Benoit, 2019]. Ankyloglossia also makes the transfer of milk less efficient, and these effects can lead to a decrease in milk supply, poor infant weight gain, prolonged feedings, and failure to thrive [Walsh and McKenna Benoit, 2019]. The intermittent loss of the oral nipple seal also leads to a clicking sound and aerophagia that may contribute to symptomatic reflux in infants [Kotlow, 2011; Siegel, 2016]. We assume that this is true also for bottle-fed infants.

Completing randomised controlled trials in this surgical field poses both an ethical and intellectual dilemma as completing a sham frenotomy for control infants is implausible. This prospective cohort study is a clinical endeavour to examine whether frenectomy is a valid treatment for restrictive tethered oral tissues, whether they are lingual, maxillary labial or buccal ties.

Methods

Patient inclusion

Participants within the study were bottle-feeding infants with untreated ankyloglossia and/or tethered maxillary labial and buccal frenums, who completed preoperative, 1-week and 1-month post-operative surveys consisting of the Revised Infant Gastroesophageal Reflux Questionnaire (I-GERQ-R), within an Australian private general dental practice setting.

Study participants were recruited from all dyads who were referred for evaluation for frenotomy if 1) the infant was less than 12 weeks of age and greater than 37 weeks gestational age; 2) solely bottle-fed infants; 3) infants who were deemed to fulfil the criteria of functional restriction of movement of the tongue, upper lip, cheeks; 4) the infant underwent surgical correction for restricted (tethered), maxillary labial frenum (upper lip-tie) and/or maxillary buccal frenums and/or ankyloglossia (tongue-tie) within an Australian private general dental practice setting by the study's principal author.

Oral assessment

All infants were initially evaluated by community lactation consultants before surgical referral as a prerequisite for consultation by the principal investigator. Latch assessment by the lactation consultants was considered in the decision-making process in whether frenotomy was offered. A targeted head and neck evaluation was performed to determine if restrictions were present, examining for maxillary bony alveolar notch-

Definition		No (%)
CORYLLOS TONGUE-TIE CLASSIFICATION		
TYPE 1	Attachment of the frenulum to the tip of the tongue	3 (7.5%)
TYPE 2	Attachment is 2-4mm behind the tip of tongue/on or behind alveolar ridge	10 (25%)
TYPE 3	Attachment to mid tongue/middle of the floor of the mouth	9 (22.5%)
TYPE 4	Attachment against the base of the tongue, thick and inelastic	18 (45%)
KOTLOW LIP-TIE CLASSIFICATION		
CLASS 1	No significant attachment	0 (0%)
CLASS 2	Attachment mostly into the gingival tissue	1 (2.5%)
CLASS 3	Attachment in front of the incisive papilla	18 (45%)
CLASS 4	Attachment into the papilla or extending into the hard palate	21 (52.5%)

Note Type 1 Coryllos TT is the most severe in anatomical appearance (100% TT), while a Class 1 Kotlow LT is the least severe.

TABLE 1 Lip and Tongue-tie Classification types and frequency Preoperatively

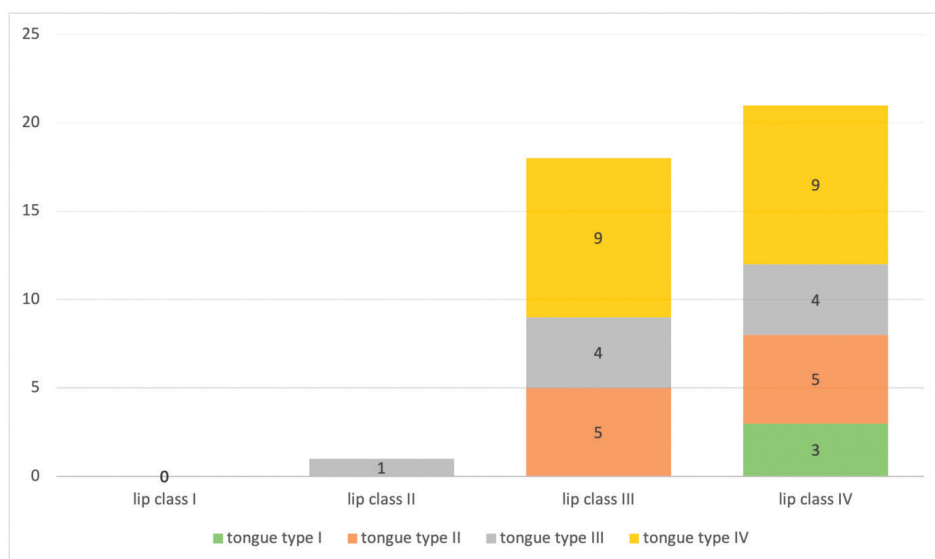


TABLE 2
Distribution of the surgery performed

ing, blanched frenula with elevation, anatomical restriction of elicited lateral lingual movement (impaired transverse tongue reflex), abnormal floor of mouth elevation with elevation of the tongue, and location of attachment of the frenula. A sucking evaluation was then performed, noting abnormal gum/lip grip pressure, cupping of the tongue against the finger, seal on the finger, and the nature of the tongue movements whilst sucking. The Bristol Tongue Assessment Tool (BTAT) / The Tongue-tie and Breastfed Babies (TABBY) assessment tool [Ingram et al., 2019] was also used. Standardised classification systems were used to describe frenula anatomy: the Kotlow upper lip-tie classification [Kotlow, 1999] and Coryllos tongue-tie classification systems [Elizabeth et al., 2004], as described in Table 1. A symptom/complaint checklist was also completed by each mother; the symptoms and frequency of symptom presentation are described in Table 2.

Surgical and study consent

Informed consent for surgery and study involvement was gained prior to surgical intervention. The study was carried out according to the Australian National Statement on Ethical Conduct in Human Research (2007, updated 2018), and followed the guidelines as stated by the Australian Government's National Health and Medical Research Council. (NHMRC)

Information gathered for the study included initial demographic details and preoperative, 1 week and 1 month post-operative surveys consisting of the Revised Infant Gastroesophageal Reflux Questionnaire (I-GERQ-R) to measure gastroesophageal reflux disease (GERD). See Appendices for Patient History Form and I-GERQ-R.

Surgical intervention

Parents completed the informed consent and the patient was moved to a laser safe dental surgery. Surgery was completed using 2 different near-infrared diode lasers.

One laser used was the 980nm wavelength diode laser (Lasotronix Smart Pro, Piaseczno Poland), with variable pulsed wave and power settings. The settings used were 4.0W, gated with 100 microsec t/on and 100 microsec t/off, and a 1470nm wavelength diode laser (Pioon S1, Wuhan Pioon Tech Co Ltd., Wuhan, China), used at 3.5W, gated with 50 millisecc t/on and 50 millisecc t/off. Among the 40 surgical procedures, the 1470

nm laser was used in 25 (62.5%) surgical procedures, and the 980 nm laser in 15 (37.5%) surgical procedures. Surgery was performed under operative microscope (Zeiss ProErgo, Germany). No local or topical anaesthesia was used.

The surgical release was completed for the tongue by elevation of the tongue with a sterile grooved tongue director as the initiated laser tip was applied to the frenulum starting at the anterior point of the frenulum, if it was attached to the alveolar ridge (anterior tie). Maxillary labial release was achieved by elevating the upper lip with gauze and removing the frenum from the alveolar ridge up to the mucogingival junction. Buccal frenal release was achieved by elevating the cheek with a retractor and then removing the frenum from the alveolar ridge up to the mucogingival junction. This was completed bilaterally in the cases where buccal frenotomy was deemed necessary. The infant was then taken back to the mother and immediately offered the bottle. Post-procedural stretching exercises were undertaken 3 times per day for 2-3 weeks by gentle massage and stretching to avoid reattachment of the tissues. Acetaminophen was suggested as an analgesic medication if required and if the infant was greater than 28 days of age.

Patients follow-up and re-assessment

All infants were seen one-week post-surgery for follow-up. If symptoms persisted or returned, or if mothers had concerns, other follow-ups were held. The one-month follow-up was by survey with the use of the SurveyMonkey electronic transfer portal.

The 12-item I-GERQ-R survey was used to evaluate the severity of symptoms associated with infant gastroesophageal reflux disease (GERD). Scoring involves the summation of the 12 questions with the score range from 0 - 40, where lower scores reflect lower symptom severity.

Exclusion criteria

Study participants were considered lost to follow up if I-GERQ-R survey evaluations were not completed within the 1-month study follow-up period. Other dyads excluded from the study had had previous treatment for RTOTS by another provider.

Statistical analyses

Quantitative variables were tested for normal distribution by a

		Total population	Lip class				Tongue Type			
			I (n=0)	II (n=1)	III (n=18)	IV (n=21)	I (n=3)	II (n=10)	III (n=9)	IV (n=18)
Gender, N (%)	female	15 (37.5)	0	0	9 (50.0)	6 (28.6)	1 (33.3)	3 (30.0)	2 (22.2)	9 (50.0)
	male	25 (62.5)	0	1 (100.0)	9 (50.0)	15 (71.4)	2 (66.7)	7 (70.0)	7 (77.8)	9 (50.0)
Age, mean days (SD; min-max)		46.8 (24.6; 8-84)	0	47(-;-)	50.7 (22.2; 11-51)	43.4 (27.0; 8-84)	18.3 (16.2; 8-37)	40.0 (18.2; 16-76)	57.6 (23.4; 20-84)	49.9 (26.0; 11-84)
Birth, N (%)	HV	26 (65.0)	0	1 (100.0)	9 (50.0)	16 (76.2)	2 (66.7)	7 (70.0)	6 (66.7)	11 (61.1)
	HC	14 (35.0)	0	0	9 (50.0)	5 (23.8)	1 (3.3)	3 (30.0)	3 (33.3)	7 (38.9)
Birth weight, mean (SD; min-max)		3.31 (0.4; 2-4)	0	3.3 (-;-)	3.2 (0.5; 2-4)	3.4 (0.4; 3-4)	3.4 (0.8; 3-4)	3.4 (0.4; 3-4)	3.3 (0.3; 3-4)	3.3 (0.4; 2-4)
Nipple shield, N (%)		2 (5.0)	0	0	0	2 (9.5)	0	0	0	2 (11.1)
EBM, N (%)		14 (35.0)	0	0	6 (33.3)	8 (38.1)	2 (66.7)	9 (9.0)	2 (22.2)	9 (50.0)
Supplementing, N (%) ²		27 (67.5)	0	1 (100.0)	13 (72.2)	13 (61.9)	1 (33.3)	9 (9.0)	8 (88.9)	9 (50.0)
Vit K, N (%)		2 (5.0)	0	0	1 (5.6)	1 (4.8)	0	0	0	2 (11.1)
Premature birth, N (%)		2 (5.0)	0	0	1 (5.6)	1 (4.8)	0	1 (10.0)	0	1 (5.6)
Meds, N (%)		4 (10.0)	0	0	1 (5.6)	3 (14.3)	0	0	1 (11.1)	3 (16.7)
Medical condition, N (%)		3 (7.5)	0	0	1 (5.6)	2 (9.5)	0	1 (10.0)	0	2 (11.1)
Diff in latch, N (%)		31 (77.5)	0	1 (100.0)	13 (72.2)	17 (81.0)	2 (66.7)	7 (70.0)	8 (88.9)	14 (77.8)
Falls asleep, N (%)		19 (47.5)	0	1 (100.0)	8 (44.4)	10 (47.6)	1 (33.3)	6 (60.0)	5 (55.6)	7 (38.9)
Slides off breast, N (%)		11 (27.5)	0	0	3 (16.7)	8 (38.1)	0	2 (20.0)	4 (44.4)	5 (27.8)
Reflux, N (%)		28 (70.0)	0	0	15 (83.3)	13 (61.9)	1 (33.3)	6 (60.0)	7 (77.8)	14 (77.8)
Poor weight gain, N (%)		7 (17.5)	0	0	2 (11.1)	5 (23.8)	0	2 (20.0)	1 (11.1)	4 (22.2)
Short sleep, N (%)		8 (20.0)	0	0	2 (11.1)	6 (28.6)	1 (33.3)	1 (10.0)	3 (33.3)	3 (16.7)
Apnoea, N (%)		11 (27.5)	0	1 (100.0)	4 (22.2)	6 (28.6)	0	3 (30.0)	5 (55.6)	3 (16.7)
Unable to keep dummy in, N (%)		20 (50.0)	0	0	9 (50.0)	7 (33.3)	2 (66.7)	5 (50.0)	4 (44.4)	9 (50.0)
Congested in am, N (%)		16 (40.0)	0	1 (100.0)	8 (44.4)	37 (46.3)	0	2 (20.0)	5 (55.6)	9 (50.0)
Congested after nap, N (%)		12 (30.0)	0	1 (100.0)	4 (22.2)	7 (33.3)	0	3 (30.0)	4 (44.4)	5 (27.8)
Gagging solid, N (%)		1 (2.5)	0	0	0	1 (4.8)	0	0	0	1 (5.6)
Be upright, N (%)		4 (10.0)	0	0	2 (11.1)	2 (9.5)	0	0	2 (22.2)	2 (11.1)
Milk leaking, N (%)		30 (75.0)	0	0	12 (66.7)	18 (85.7)	2 (66.7)	10 (100.0)	5 (55.6)	13 (72.2)
Lip class, N (%)	I class	0 (0.0)	-	-	-	-	0 (0.0)	0	0	0
	II class	1 (2.8)	-	-	-	-	0	0	1 (11.1)	0
	III class	18 (45.0)	-	-	-	-	0	5 (50.0)	4 (44.4)	9 (50.0)
	IV class	21 (52.5)	-	-	-	-	3 (100.0)	5 (50.0)	4 (44.4)	9 (50.0)
Tongue Type N (%)	Type I	3 (7.5)	0	0	0	3 (14.3)	-	-	-	-
	Type II	10 (25.0)	0	0	5 (27.8)	5 (23.8)	-	-	-	-
	Type III	9 (22.5)	0	1 (100.0)	4 (22.2)	4 (19.0)	-	-	-	-
	Type IV	18 (45.0)	0	0	9 (50.0)	9 (42.9)	-	-	-	-
Surgery performed, N (%) ¹	Lip surgery	2 (5.0)	0	0	0	2 (9.5)	0	0	0	2 (11.1)
	Tongue surgery	8 (20.0)	0	1 (100.0)	7 (38.9)	17 (81.0)	0	2 (20.0)	2 (22.2)	4 (22.2)
	Lip and tongue surgery	28 (70.0)	0	0	11 (61.1)	17 (81.0)	3 (100.0)	8 (80.0)	6 (66.7)	11 (61.1)
	Lip, tongue and buccal surgery	2 (5.0)	0	0	0	2 (9.5)	0	0	1 (11.1)	1 (5.6)
Wavelength, N (%)	980 nm	15 (37.5)	0	0	2 (22.2)	11 (52.4)	1 (33.3)	3 (30.0)	3 (33.3)	8 (44.4)
	1470 nm	25 (62.5)	0	1 (100.0)	14 (77.8)	10 (47.6)	2 (66.7)	7 (70.0)	6 (66.7)	10 (55.6)

TABLE 3. Demographic, epidemiological and clinical data of overall population and stratified according by lip class and tongue class.

		Laser wavelength		Surgery performed			
		980 nm (Lasotronix Smart Pro) (n=15)	1470 nm (Pioon S1) (n=25)	Lip surgery (n=2)	Tongue surgery (n=8)	Lip and tongue surgery (n=28)	Lip, tongue and buccal surgery (n=2)
Gender, N (%)	female	5 (33.3)	10 (40.0)	0	1 (12.5)	14 (50.0)	0
	male	10 (66.7)	15 (60.0)	2 (100.0)	7 (87.5)	14 (50.0)	2 (100.0)
Age, mean days (SD; min-max)		54.5 (26.7; 10-84)	42.2 (22.5; 8-81)	48.0 (28.3; 28-64)	32.9 (16.2; 11-59)	48.1 (24.9; 8-84)	82.0 (2.8; 80-84)
Birth, N (%)	HV	12 (80.0)	14 (56.0)	1 (50.0)	4 (50.0)	20 (71.4)	1 (50.0)
	HC	3 (20.0)	11 (44.0)	1 (50.0)	4 (50.0)	8 (28.6)	1 (50.0)
Birth weight, mean (SD; min-max)		3.3 (0.4; 10-84)	42.2 (22.5; 8-81)	3.5 (0.1; 3-4)	3.2 (0.5; 3-4)	3.3 (0.4; 2-4)	3.6 (0.1; 4-4)
Nipple shield, N (%)		2 (13.3)	0	0	0	2 (7.1)	0
EBM, N (%)		6 (40.0)	8 (32.0)	0	4 (50.0)	9 (32.1)	1 (50.0)
Supplementing, N (%)		9 (60.0)	18 (72.0)	0	6 (75.0)	20 (71.4)	1 (50.0)
Vit K, N (%)		2 (13.3)	0	0	0	2 (7.1)	0
Premature birth, N (%)		2 (13.3)	0	0	0	2 (7.1)	0
Meds, N (%)		3 (20.0)	1 (4.0)	0	0	4 (14.3)	0
Medical condition, N (%)		2 (13.3)	1 (4.0)	0	1 (12.5)	2 (7.1)	0
Diff in latch, N (%)		11 (73.3)	20 (80.4)	1 (50.0)	6 (75.0)	22 (78.6)	2 (100.0)
Falls asleep, N (%)		5 (33.3)	14 (56.0)	0	3 (37.5)	16 (57.1)	0
Slides off breast, N (%)		5 (33.3)	6 (24.0)	0	1 (12.5)	8 (28.6)	2 (100.0)
Reflux, N (%)		12 (80.0)	16 (64.0)	1 (50.0)	5 (62.5)	21 (75.0)	1 (50.0)
Poor weight gain, N (%)		1 (6.7)	6 (24.0)	0	1 (12.5)	6 (21.4)	0
Short sleep, N (%)		4 (26.7)	4 (16.0)	1 (50.0)	0	6 (21.4)	1 (50.0)
Apnoea, N (%)		5 (33.3)	6 (24.0)	0	2 (25.0)	8 (28.6)	1 (50.0)
Unable to keep dummy in, N (%)		9 (60.0)	11 (44.0)	1 (50.0)	4 (50.0)	15 (53.6)	0
Congested in am, N (%)		5 (33.3)	11 (44.0)	2 (100.0)	2 (25.0)	12 (42.9)	0
Congested after nap, N (%)		3 (20.0)	9 (36.0)	2 (100.0)	2 (25.0)	8 (28.6)	0
Gagging solid, N (%)		1 (6.7)	0	0	0	1 (3.6)	0
Be upright, N (%)		2 (13.3)	2 (8.0)	0	0	4 (14.3)	0
Milk leaking, N (%) ¹		12 (80.0)	18 (72.0)	2 (100.0)	2 (25.0)	24 (85.7)	2 (100.0)
Lip class, N (%) ¹	I class	0	0	0	0	0	0
	II class	0	1 (4.0)	0	1 (12.5)	0	0
	III class	4 (26.7)	14 (56.0)	0	7 (87.5)	11 (39.3)	0
	IV class	11 (73.3)	10 (40.0)	2 (100.0)	0	17 (60.7)	2 (100.0)
Tongue class, N (%)	Type I	1 (6.7)	2 (8.0)	0	0	3 (10.7)	0
	Type II	3 (20.0)	7 (28.0)	0	2 (25.0)	8 (28.6)	0
	Type III	3 (20.0)	6 (24.0)	0	2 (25.0)	6 (21.4)	1 (50.0)
	Type IV	8 (53.3)	10 (40.0)	2 (100.0)	4 (50.0)	11 (39.3)	1 (50.0)
Surgery performed, N (%)	Lip surgery	1 (6.7)	1 (4.0)	-	-	-	-
	Tongue surgery	2 (13.3)	6 (24.0)	-	-	-	-
	Lip and tongue surgery	10 (66.7)	18 (72.0)	-	-	-	-
	Lip, tongue and buccal surgery	2 (13.3)	18 (72.0)	-	-	-	-
Wavelength, N (%)	980 nm	-	-	1 (50.0)	2 (25.0)	10 (35.7)	2 (100.0)
	1470 nm	-	-	1 (50.0)	6 (75.0)	18 (64.3)	0

¹ Statistically significant difference between surgery performed - chi-square test p<0.05

TABLE 4 Demographic, epidemiological and clinical data stratified according by laser wavelength and surgery performed.

		I-GERQ-R (mean, SD; min-max)		
		Preoperative	1 week post-operative	1 month post-operative
Total sample (n=40)**		16.6 (6.1; 8-28)	14.1 (4.2; 6-24)	9.1 (4.5; 3-27)
Lip class				
	I (n=0)	-	-	-
	II (n=1)	18.0 (-;-)	16.0 (-;-)	11.0 (-;-)
	III (n=18)**	18.8 (4.9; 10-28)	13.7 (5.3; 6-24)	8.7 (6.0; 3-27)
	IV (n=21)**	16.3 (5.4; 8-25)	14.3 (3.2; 8-20)	9.4 (3.0; 3-15)
Tongue Type				
	I (n=3)	12.0 (4.6; 8-17)	14.0 (2.7; 11-16)	9.3 (2.9; 8-37)
	II (n=10)	14.8 (5.2; 8-23)	14.4 (3.8; 8-19)	9.3 (6.9; 3-27)
	III (n=9)*	16.2 (5.2; 8-25)	13.0 (5.6; 6-20)	9.7 (4.8; 3-15)
	IV (n=18)**	18.5 (4.4; 11-28)	14.5 (4.1; 10-24)	8.7 (3.3; 3-15)
Laser wavelength				
	980 (n=15)**	17.4 (4.5; 8-24)	15.2 (3.8; 10-24)	9.2 (3.5; 3-15)
	1470 (n=25)**	16.1 (5.4; 8-28)	13.4 (4.4; 6-21)	9.1 (5.2; 3-27)
Surgery performed				
	Lip surgery (n=2)	17.5 (2.1; 16-19)	14.0 (5.7; 10-18)	9.0 (1.4; 8-10=)
	Tongue surgery (n=8)*	14.6 (3.2; 10-18)	13.3 (4.1; 6-19)	9.8 (3.4; 4-15)
	Lip and tongue surgery (n=28)**	17.2 (5.4; 8-28)	14.2 (4.4; 6-24)	9.1 (5.2; 3-27)
	Lip, tongue and buccal surgery (n=2)	15.0 (9.9; 8-22)	16.5 (3.5; 14-19)	7 (1.4; 6-8)

* Differences between times - ANOVA test= $p<0.05$

** Differences between times - ANOVA test= $p<0.001$

TABLE 5 I-GERQ scores in total sample and stratified by lip class, tongue class, laser wavelength and surgery performed.

Kolmogorov-Smirnov test: parametric variables were tested by means of two-tailed analysis of variance (ANOVA), whereas Mann-Whitney test was used for non-parametric variables. Furthermore, Bonferroni corrections were conducted to analyse differences between groups if statistically significant differences were found by ANOVA test. Binomial or discontinuous variables were assessed by means of the chi-square test and Fisher's exact test. Linear regression model was calculated to understand the effect of time on I-GERQ-R. Statistics was performed with IBM SPSS Statistics ver. 25 for Apple (IBM Corp., Armonk, NY).

Results

Forty (40) participant families were enrolled in the study with 15 (37.5%) female infants and 25 (62.5%) male. The median age of 47 days and a median current weight of 4.35kg. The median birth weight was 3.3 kg. The infants were all born in hospital, 65% were vaginally delivered and 35% via caesarian section. Two (2) infants noted as premature did not receive vitamin K injection at birth but did have oral vitamin K prior to frenal surgery performed in this study at 14 and 21 days corrected age. Medications being received were all paediatric omeprazole and medical conditions noted were all reflux. Anatomic classifications preoperatively are shown in Table 1. Twenty eight (28) infants (70%) received both lip and tongue surgery, followed by eight (8) infants (20%) who received only tongue surgery, two (2) infants (5%) who received tongue, lip and buccal frenum surgery and two (2) infants (5%) received only lip surgery. Maternal complaints from the initial questionnaire and their prevalence are detailed in Table 3.

Oral examination revealed, according to Coryllos tongue classification, 18 tongue frenums were Type 4 (45,0%), 9 were in Type 3 (22,5%), 10 were in Type 2 (25,0%) and 3 were in Type 1 (7,5%) and according to Kotlow lip frenum classification, a total of 21 class 4 lip frenum (52,5%), 18 class 3 (45,0%) and

1 class 2 lip frenum (2,8%).


Following surgery, statistically significant improvement in I-GERQ scores was reported between preoperative (16.6, SD: 6.1; min-max: 8-28), 1 week (14.1, SD: 4.2; min-max: 6-24) and 1 month I-GERQ-R total scores (9.1, SD: 4.5; min-max: 3-27) (ANOVA test - $P < .001$) (Table 3). Bonferroni correction analysis showed a statistically significant improvement between preoperative and 1 month I-GERQ scores and between 1 week and 1 month I-GERQ scores (ANOVA test - $P < .001$). No difference was found between pre-operative and 1 week I-GERQ scores.

A subgroup analysis was conducted for lip class, tongue class, surgery performed and laser wavelength (Table 4). A highly significant improvement ($P < .001$) was found in those infants affected by posterior tongue-tie (Type 3 and 4 tongue frenum and class 4 lip frenum). Bonferroni correction analysis showed a statistically significant improvement between preoperative and 1 month I-GERQ scores and between 1 week and 1 month I-GERQ scores (ANOVA test - $P < .05$). In class 4 tongue frenum, pre-operative and 1 week I-GERQ scores was statistically different (ANOVA test - $P < .05$).


Regarding the surgical procedures performed, tongue surgery and combined lip and tongue surgery procedures showed a highly improvement (respectively $P < .05$ and $P < .001$). Moreover, Bonferroni correction analysis showed a significant reduction between pre-operative and 1 month I-GERQ scores and between 1 week and 1 month I-GERQ scores (ANOVA test - $P < .05$). No difference was found between pre-operative and 1 week I-GERQ scores.

According to wavelength laser, both 980nm and 1470 nm produced significant improvement in I-GERQ score (ANOVA test - $P < .001$). Bonferroni correction analysis showed a statistically significant improvement between pre-operative and 1 month I-GERQ scores and between 1 week and 1 month I-GERQ scores (ANOVA test - $P < .05$). No difference was found between pre-operative and 1 week I-GERQ scores.

A linear correlation was detected between time and I-GERQ-



Dr Philip L. Hand
DENTAL SURGEON,
BIBB (DENTAL) NO. 2

More than  just a great Smile.™

Marrion & Hand Pty Ltd
Louis Professional Suites
Suite 3, 23 Louis Street
Airport West 3042
Telephone: 03 9338 2455
Fax: 03 9338 5781

Patient's Name _____ Birth Date _____ Today's Date _____

Parents' Names _____ Email _____

Address _____ Phone _____

Male/Female Home Birth _____ Hospital Birth _____ Vaginal Birth _____ C-Section birth _____

Medical Problems _____ Heart disease _____ Bleeding Disorders _____ Other _____ Birth weight _____ Present weight _____

1. Are you presently breastfeeding? Yes _____ No _____
If no, how long since you stopped breastfeeding? _____

2. Are you presently using a nipple shield? Yes _____ No _____

3. Are you choosing not to breastfeed? Yes _____ No _____

4. Are you pumping breast milk? Yes _____ No _____

5. Are you supplementing using a bottle? Yes _____ No _____

6. Are you using an SNS device? Yes _____ No _____

7. Do you or any immediate family members have any bleeding disorders? Yes _____ No _____

Medical History: Has your child experienced any of the following problems or treatment?
1. Infants are usually given Vitamin K at birth to prevent bleeding in the first 8 weeks of life. Did you sign any waiver to refuse the administration of vitamin K? Yes _____ No _____

2. Was your infant premature? Yes _____ No _____

3. Does your infant have any heart disease? Yes _____ No _____

4. Has your infant had any surgery? Yes _____ No _____

5. Is your child taking any medications? Yes _____ No _____
Reflex Med's _____ Thrush med's _____
Name of medications _____

6. Does your child have any other medical conditions? _____

<p>Mother's Symptoms</p> <p>_____ Cracked, cracked or blanching of nipples</p> <p>_____ Painful latching of infant onto the breast</p> <p>_____ Gumming or chewing of the nipples</p> <p>_____ Infant unable to achieve a successful, tight latch</p> <p>_____ Poor or incomplete breast drainage</p> <p>_____ Infected nipples or breasts</p> <p>_____ Abraded nipples</p> <p>_____ Blocked ducts</p> <p>_____ Mastitis</p> <p>_____ Nipple thrush</p> <p>_____ Feelings of depression</p> <p>_____ Oversupply of breast milk</p> <p>_____ Undersupply of breast milk</p>	<p>Infant's Symptoms</p> <p>_____ Difficulty in achieving a good latch</p> <p>_____ Falls asleep while attempting to nurse</p> <p>_____ Slides off the breast when attempting to latch</p> <p>_____ Reflux (Clicking, swallowing air during nursing)</p> <p>_____ Poor weight gain</p> <p>_____ Short sleep episodes (feeding every 1-2 hours)</p> <p>_____ Apnoea – snoring, heavy noisy breathing</p> <p>_____ Unable to keep pacifier/dummy in the infant's mouth</p> <p>_____ Waking up congested in the morning</p> <p>_____ Waking up congested from nap time</p> <p>_____ Gagging when attempting to introduce solid foods</p> <p>_____ Only sleeping when in upright position or in car seat</p> <p>_____ Milk leaking out sides of mouth whilst feeding</p>
---	---

Paediatrician _____ Phone number _____

Address _____

GP Doctor _____ Phone number _____

Has your Doctor or Paediatrician evaluated your infant's lip and tongue ties? Yes _____ No _____

Lactation Consultant _____ Phone number _____

Address _____


Who referred you to our office? _____

Did you use the internet to find our office? Yes _____ No _____


Have you visited our website? Yes _____ No _____

Additional comments _____

Signed _____



Dr Philip L. Hand
DENTAL SURGEON,
BIBB (DENTAL) NO. 2

More than  just a great Smile.™

Marrion & Hand Pty Ltd
Louis Professional Suites
Suite 3, 23 Louis Street
Airport West 3042
Telephone: 03 9338 2455
Fax: 03 9338 5781

Patient's Name _____ Today's Date _____

Infant Gastroesophageal Reflux Questionnaire (I-GERQ-R)

1. During the past week, how often did the baby usually spit-up (anything coming out of the mouth) during a 24-hour period?

Less than once
1 to 3 times
4 to 6 times
More than 6 times

2. During the past week, how much did the baby usually spit-up (anything coming out of the mouth) during a typical episode?

Did not spit up
Less than 1 tablespoonful
1 tablespoonful to 4 tablespoons
More than 4 tablespoons to half the feeding
More than half the feeding

3. During the past week, how often did spitting up (anything coming out of the mouth) seem to be uncomfortable for the baby, for example, crying, fussing, irritability, etc.?

Never
Rarely
Sometimes
Often
Always

4. During the past week, how often did the baby refuse a feeding even when hungry?

Never
Rarely
Sometimes
Often
Always

5. During the past week, how often did the baby stop eating soon after starting even when hungry?

Never
Rarely
Sometimes
Often
Always

6. During the past week, did the baby cry a lot during or within 1 hour after feedings?

Never
Rarely
Sometimes
Often
Always

7. During the past week, did the baby cry or fuss more than usual?

Never
Rarely
Sometimes
Often
Always

8. During the past week, on average how long did the baby cry or fuss during a 24 hour period?

Less than 10 minutes
10 minutes to 1 hour
More than 1 hour but less than 3 hours
3 or more hours

9. During the past week, how often did the baby have hiccups?

Never
Rarely
Sometimes
Often
Always

10. During the past week, how often did the baby have episodes of arching back?

Never
Rarely
Sometimes
Often
Always

11. During the past week, has the baby stopped breathing while awake or struggled to breathe?

No
Yes

12. During the past week, has the baby turned blue or purple?

No
Yes

R total scores
($\beta=-0.55$; $R^2=0.2$; $p<0.001$).

Discussion


Surgical techniques

Surgical scissors remain the tool most frequently used for frenotomy. Results of lingual frenotomy conventionally released with scissors however can be varied, as an incomplete release is common. As the area bleeds, intra-operative adjustments can be difficult due to bleeding obscuring the surgical field. We aim to achieve a diamond shaped wound under the tongue, but this is operator sensitive and therefore not predictable. Anatomical conditions can contraindicate the lateral extension of the incision on occasions making the diamond shape impossible.

Great care of salivary gland orifices and ducts was taken during this stage, and then tissue behind the sublingual caruncle in the midline was removed overlying the genioglossus muscle to the extent of ≤ 1 mm in depth. The complete release of the mucosa was achieved by carefully releasing the frenum laterally on both sides of the midline wound, taking great care to not disturb the overlying fascia of the genioglossus muscle, or the lingual vessels present in this area.

During the surgery there is no need to create a diamond shaped wound by cutting laterally in the surgical area, because this is the natural shape the tissue takes when a sufficiently

If breast feeding your baby, please place a mark on the line for how breastfeeding feels for you.



Please return completed form to reception@marrionlighthand.com.au

deep horizontal cut through the frenum is made. Strict attention to detail whilst performing the surgery is paramount to avoid vessels when cutting horizontally. The frenum is triangular, and when a triangular prism is cut through, the top and bottom flip out, forming a diamond shaped wound [Baxter, 2018]. The use of a dental operating microscope (DOM) is of significant advantage to accomplish this.

If the frenum is only clipped and only the anterior tongue-tie has been released, a small vertical line-shaped wound will be noted as the posterior component of the tongue-tie still exists. This incomplete release leaves a thick band of tissue that still holds the tongue in a downward position and limits mobility for nursing, speech, and/or feeding. This thick band does not go away over time, and these restrictions of the tongue may cause functional issues throughout life [Baxter, 2018].

Frenotomy is considered a safe procedure in almost all cases. The most common risks include infection and minor bleeding at the site. Other issues are pain and discomfort, poor feeding, weight loss, pallor/anaemia, excess scarring, and injury to the salivary ducts and glands that are located in the floor of the mouth, near the frenum.

A recent consensus statement in Australia (Australian Dental Association, 2020) has been published highlighting potential problems with surgery and ankyloglossia. It is important to note that this surgery involves infants, our most vulnerable patients and that all surgery has associated risk. A systematic review of frenotomy found an overall rate of 1% for minor complications, with minor bleeding being the most frequent [Constantine et al., 2011]. Complications have generally been published as case reports, including a report of two cases of hypovolaemic shock [Tracy et al., 2017]. The use of diode lasers, for their specific high absorption in haemoglobin and oxyhaemoglobin, is very safe for this procedure in infants, where the fibrous component is less pronounced than in children and youths, and near infrared lasers can perform a precise incision and effective coagulation. The high control of bleeding also allows safer and better view of the surgical area, allowing more precise release. Most research studies that have been done on tongue tie release report no complications occurring in their cohorts [Buryk et al., 2011], thus lending weight to the idea that frenotomy is, in most cases, without significant morbidity [Walsh and McKenna Benoit, 2019]. Within this study, no complications were reported following any procedure.

Stretching exercises

Post-procedure stretching exercises within this study were advised to be completed 3 times per day by gently massaging the wounds and by gentle elevation of the lip/tongue/cheeks (depending on the surgery completed) for 3 weeks.

Post-operative wound care (wound stretching) is a topic of contention with Bhandakar et al. [2022] finding that improvement in breast feeding and recurrence after frenotomy were similar between massage and non massage groups. O'Callahan et al. [2013] did not find it safe and effective in preventing frenulum reattachment whilst in another study the opposite was found. [Demyati et al., 2014]. It seems reasonable to assume that keeping the wound from sticking back together other than by the secondary intention intended, will reduce/negate reattachment of the wound. In the principal author's experience, one can be assured of reattachment if stretches are not completed post-surgery. Further studies are required to determine what association there may be between stretching exercises preventing regrowth/reattachment of the frenulum and reoccurrence of symptoms after frenectomy.

When conservative treatment such as lactation consultant support and bodywork have proven ineffective then it is shown in this study that surgical intervention can benefit both mother and child.

The large number of posterior tongue-ties (type 3 and 4) within the referred (and successfully treated) infants in this study, indicates that the still widely disregarded sub mucosal (posterior) tongue-tie (67.5%) demonstrates a population of infants who are having considerable feeding problems. The tongue must be palpated to feel the restriction. A coated dorsum of the tongue (not thrush but milk residue), poor lift and/or lateral movement of the tongue, may indicate the need for intervention. Without the knowledge to diagnose this restriction, this cohort of infants and their mothers struggling to feed is being ignored. It remains a major paradigm shift within the lactation and medical community for acceptance of what we have shown is a significant issue.

Maxillary labial restriction due to a restrictive lip-tie can affect the quality of the latch. Where indicated by poor shallow latch an upper labial frenotomy was also performed and the results from this study suggests that this was also beneficial. Infants requiring tongue-tie and lip-tie releases can open their mouth wider immediately after release. This increased opening allows a deeper latch to the bottle. In this study 99% of the infants also had a low insertion of the maxillary labial frenum, a figure comparable to the studies of Flinck et al. [1994]. In newborns, the attachment location of the labial frenulum is typically at the gingival margin or on to the palate, comprising more than 93% of all normal labial frenae.

Within this study these infants are a select group that has firstly been referred to a general dental practice and are also determined to require surgery. The insertion point of the frenum is not the determining factor as to whether surgery is undertaken; this is determined after considering whether failure for the lip to flange whilst nursing, lip dimpling, bony remodeling of the alveolar ridge or blanching of the frenulum and mucosa over the alveolar ridge and incisive papilla upon elevation of the lip.

Crying is common in infants and signs and symptoms attributed to gastrointestinal reflux are common. This is distressing to families, and often results in the use of medication [Smith et al., 2013]. The use of PPIs (proton pump inhibitors) in infants and children has increased in recent years. In the 5-year period between 1999 and 2004 there was a greater than 7-fold increase in the prescription of PPIs for infants [Barron et al., 2007]. In a systemic review by Gieruszczak-Bialek et al, they found that there was no effect of PPIs on crying and irritability in infants Gieruszczak-Bialek et al. [2015].

Using a validated, patient-based instrument we were able to demonstrate a reduction in GERD symptoms scores after frenotomy, suggesting that lingual restriction may be associated with infant reflux symptoms, and that correction of latch abnormalities attributed to ankyloglossia significantly improves reflux scores at 1 week and 1-month post-procedure.

The 12 item I-GERQ-R survey was used to evaluate the severity of symptoms associated with infant gastroesophageal reflux disease (GERD). It is a reliable and validated measure of infant GERD symptoms. The I-GERQ-R can be used in the diagnosis of infant GERD to differentiate cases from those infants without sufficient symptoms for the diagnosis, to monitor treatment outcomes in clinical practice, and to serve as an evaluative tool in clinical trials [Kleinman et al, 2006; Orenstein, 2010]. Scoring involves the summation of the 12 questions with the score range from 0–40, where lower scores reflect lower symptom severity. Smith et al. [2020] in their structured review of 42

papers relating to I-GERQ-R found a threshold for clinically important difference (CID) for the I-GERQ-R of around 6 could signify a clinically important difference for this instrument. The lower limit of the 95% confidence interval suggested a threshold of 3 to 4 could represent a minimally important difference. This study has measured reflux symptomatology before and after frenotomy. Infant reflux is multifactorial in nature. Siegel [2016] has suggested that the mechanism that explains the improvement of the reflux scores is a resolution of aerophagia. The reflux improvement seen in this cohort soon after the procedure suggests that the decrease in aerophagia is due to an improved latch. A spontaneous resolution of other factors contributing to reflux during the period of the study is unlikely.

Conclusion

Infants in this study were only seen after having sought lactation advice and were only offered surgical intervention when restrictive tethered tissues (RTOTS) were found. Laser surgical release of frenal restriction used in this study, provided significant average improvement in all categories of restriction treated. These improvements were seen in feeding outcomes for these bottle-fed infants. Improvements were evaluated at the one week and one-month postoperative assessments in all categories treated (lip, tongue, lip/tongue and lip/cheek/tongue). All classes of tongue ties treated showed significant improvement.

References

- Amir, L. H. and Donath, S. M. 'Socioeconomic status and rates of breastfeeding in Australia: Evidence from three recent national health surveys', *Medical Journal of Australia*, 2008 189(5), pp. 254–256. doi: 10.5694/j.1326-5377.2008.tb02016.x.
- Australian Dental Association (2020) Ankyloglossia and Oral Frena Consensus Statement.
- Australian Institute of Health and Welfare 2011 (2011) 2010 Australian National Infant Feeding Survey: Indicator Results (Cat. no. PHE 156), AIHW. doi: 10.1109/TMI.2002.801172.
- Australian National Standard on Ethical Conduct - The National Statement on Ethical Conduct in Human Research (2007) (National Statement (2007), and as updated, consists of a series of guidelines made in accordance with the National Health and Medical Research Council Act 1992. Reference number E72 ISBN 1864962755
- Barron J. J., Tan H., Spalding J, Bakst A, Singer J. 'Proton pump inhibitor utilization patterns in infants.', *Journal of pediatric gastroenterology and nutrition*, 2007 45(4), pp. 421–427. doi: 10.1097/MPG.0b013e31812e0149.
- Baxter, R. "Tongue-Tied: How a Tiny String Under the Tongue Impacts Nursing, Speech, Feeding, and More". 2018 Tongue-tie Center.
- Bhandarkar, K.P., Dar, T., Karia, L., & Upadhyaya, M. Post Frenotomy Massage for Ankyloglossia in Infants-Does It Improve Breastfeeding and Reduce Recurrence? *Maternal and Child Health Journal*, 2022 <https://doi.org/10.1007/s10995-022-03454-x>
- Buryk, M., Bloom, D. and Shope, T. 'Efficacy of neonatal release of ankyloglossia: a randomized trial.', *Pediatrics*, 2011 128(2), pp. 280–288. doi: 10.1542/peds.2011-0077.
- Caloway, C, Hersh C, Baars R, Sally S, Gillian Diercks G, Hartnick C, Feeding Evaluation with Frenotomy Rates in Infants with Breastfeeding Difficulties', *JAMA Otolaryngology - Head and Neck Surgery*, 2019 145(9), pp. 817–822. doi: 10.1001/jamaoto.2019.1696.
- Center for Disease Control and Prevention. Breastfeeding report card United States, 2018. Published 2018. Accessed June 9, 2021 <https://www.cdc.gov/breastfeeding/pdf/2018breastfeedingreportcard.pdf>
- Colin, W. B. and Scott, J. A. 'Breastfeeding: reasons for starting, reasons for stopping and problems along the way.', *Breastfeeding review* : professional publication of the Nursing Mothers' Association of Australia, 2002 10(2), pp. 13–19.
- Constantine, A. H., Williams, C. and Sutcliffe, A. G. 'A systematic review of frenotomy for ankyloglossia (tongue tie) in breast fed infants', *Archives of Disease in Childhood*, 2011 96(Suppl 1), p. A62 LP-A63. doi: 10.1136/adc.2011.212563.144.
- Demirgüne Ef, Ersoy-Evans S, Karaduman A. GAPO syndrome with the novel features of pulmonary hypertension, ankyloglossia, and prognathism. *J Med Genet Actions*. 2009 Feb 15;149A(4):802-5. doi: 10.1002/ajmg.a.32686.
- Demyati, E., Stern, M., Goldfarb, L., Srinivasan, A., Mitnick, H., & Dobrich, C. 'Ankyloglossia in breastfeeding infants: Stretching exercises post-frenotomy and the efficacy of the procedure. ILC Abstracts', *Journal of Human Lactation*, 2014 30(4), p. 506. Available at: doi:10.1177/0890334414548676.
- Elizabeth, Coryllos and Salloum, A. C. 'Breastfeeding : Best for Baby and Mother', *American Academy of Pediatrics*, (Summer 2004), pp. 1–12. Available at: http://www2.aap.org/breastfeeding/files/pdf/BBM-8-27_Newsletter.pdf.
- Flinck, A. Paludan A, Matsson L, Holm AK, Axelsson I. Oral findings in a group of newborn Swedish children.', *International journal of paediatric dentistry*, 1994 4(2), pp. 67–73. doi: 10.1111/j.1365-263x.1994.tb00107.x.
- Geddes D, Langton D, Gollow I, Jacobs L, Hartmann P, Simmer K. 'Frenulotomy for breastfeeding infants with ankyloglossia: Effect on milk removal and sucking mechanism as imaged by ultrasound', *Pediatrics*. 2008 doi: 10.1542/peds.2007-2553.
- Ghaheer B, Cole M, Fausel S, Chuop M, Mace J. 'Breastfeeding improvement following tongue-tie and lip-tie release: A prospective cohort study', *Laryngoscope*. 2017 doi: 10.1002/lary.26306.
- Gieruszczak-Białek D, Konarska Z, Skórka A, Vandenplas Y, Szajewska H. 'No effect of proton pump inhibitors on crying and irritability in infants: systematic review of randomized controlled trials.', *The Journal of pediatrics*, 2015 166(3), pp. 767–770.e3. doi: 10.1016/j.jpeds.2014.11.030.
- Hand P, Olivi G, Lajolo C, Gioco G, Marigo L, Castagnola R, Cordaro M. Short lingual frenum in infants, children and adolescents. Part 1: Breastfeeding and gastroesophageal reflux disease improvement after tethered oral tissues release. *Eur J Paediatr Dent*. 2020 Dec;21(4):309-317. doi: 10.23804/ejpd.2020.21.04.10. PMID: 33337908.
- Huang YS, Quo S, Berkowski JA and Guillemainault C, Short Lingual Frenulum and Obstructive Sleep Apnea in Children. *Int J Pediatr Res* 2015, 1:1.
- Infant Feeding Guidelines. National Health and Medical Research Council: Canberra, 2012. (2012). National Health and Medical Research Council.
- Ingram J, Copeland M, Johnson D, Emond A. 'The development and evaluation of a picture tongue assessment tool for tongue-tie in breastfed babies (TABBY)', *International Breastfeeding Journal*. 2019 doi: 10.1186/s13006-019-0224-y.
- Kleinman L, Rothman M, Strauss R, Orenstein S, Nelson S, Vandenplas Y, Cucchiara S, Revicki D. 'The Infant Gastroesophageal Reflux Questionnaire Revised: Development and Validation as an Evaluative Instrument', *Clinical Gastroenterology and Hepatology*, 2006 4(5), pp. 588–596. doi: 10.1016/j.cgh.2006.02.016.
- Kotlow, L. 'Infant Reflux and Aerophagia Associated with the Maxillary Lip-tie and Ankyloglossia (Tongue-tie)', *Clinical Lactation*. 2011 doi: 10.1891/215805311807011467.
- Kotlow, L. A. 'Ankyloglossia (tongue-tie): a diagnostic and treatment quandary.', 1999 Quintessence international (Berlin, Germany : 1985).
- O'Callahan, C., Macary, S. and Clemente, S. 'The effects of office-based frenotomy for anterior and posterior ankyloglossia on breastfeeding.', *International journal of pediatric otorhinolaryngology*, 2013 77(5), pp. 827–832. doi: 10.1016/j.ijporl.2013.02.022.
- Olivi G, Signore A, Olivi M, Genovese MD. Lingual frenectomy: functional evaluation and new therapeutic approach. *Eur J Paediatr Dent*. 2012 Jun;13(2):101-6.
- Orenstein, S. R. 'Symptoms and Reflux in Infants: Infant Gastroesophageal Reflux Questionnaire Revised (I-GERQ-R)—Utility for Symptom Tracking and Diagnosis', *Current Gastroenterology Reports*, 2010 (6), pp. 431–436. doi: 10.1007/s11894-010-0140-1.
- Pompéia LE, Ilinsky RS, Ortolani CLF, Faltin K Júnior. ANKYLOGLOSSIA AND ITS INFLUENCE ON GROWTH AND DEVELOPMENT OF THE STOMATOGNATHIC SYSTEM. *Rev Paul Pediatr*. 2017 Apr-Jun;35(2):216-221. doi: 10.1590/1984-0462/2017;35;2;00016. PMID: 28977337; PMCID: PMC5496731.
- Pransky, S. M., Lago, D. and Hong, P. 'Breastfeeding difficulties and oral cavity anomalies: The influence of posterior ankyloglossia and upper-lip ties.', *International journal of pediatric otorhinolaryngology*, 2015 79(10), pp. 1714–1717. doi: 10.1016/j.ijporl.2015.07.033.
- Puapornpong P, Paritakul P, Suksamrongsong M, Srisuwan S, Ketsuwan S. Nipple Pain Incidence, the Predisposing Factors, the Recovery Period After Care Management, and the Exclusive Breastfeeding Outcome. *Breastfeed Med*. 2017 Apr;12:169-173. doi: 10.1089/bfm.2016.0194. Epub 2017 Mar 9. PMID: 28278382.
- Siegel, S. (2016) 'Aerophagia Induced Reflux in Breastfeeding Infants With Ankyloglossia and Shortened Maxillary Labial Frenula (Tongue and Lip Tie).', *International Journal Of Clinical Pediatrics*, 5(1), pp. 6–8.
- Smith AB, Fawkes N, Kotze H, Hodgkinson V, Coyle C. 'Clinically Meaningful Difference for the Infant Gastroesophageal Questionnaire Revised version (I-GERQ-R): A Quantitative Synthesis', *Patient Related Outcome Measures*, 2020 Volume 11, pp. 87–93. doi: 10.2147/prom.s238673.
- Smith C, Israel D, Schreiber R, Goldman R. 'Proton pump inhibitors for irritable infants.', *Canadian family physician Medecin de famille canadien*, 2013 59(2), pp. 153–156.
- Tracy L, Gomez G, Overton L, McClain W. 'Hypovolemic shock after labial and lingual frenulectomy: A report of two cases.', *International journal of pediatric otorhinolaryngology*, 2017 100, pp. 223–224. doi: 10.1016/j.ijporl.2017.07.013.
- Vaz AC, Bai PM. Lingual frenulum and malocclusion: An overlooked tissue or a minor issue. *Indian J Dent Res* 2015. PMID: 26672418.
- Victoria C, Bahl R, Barros A, França G, Horton S, Krasevec J, Murch S, Sankar M, Walker N, Rollins N. 'Breastfeeding in the 21st century: Epidemiology, mechanisms, and lifelong effect', *The Lancet*, 2016 387(10017), pp. 475–490. doi: 10.1016/S0140-6736(15)01024-7.
- Walsh, J. and McKenna Benoit, M. 'Ankyloglossia and Other Oral Ties', *Otolaryngologic Clinics of North America*. 2019 doi: 10.1016/j.otc.2019.06.008.
- WHO Resolution WHA 71.9 Infant and your child feeding. 2018 https://apps.who.int/iris/bitstream/handle/10665/279517/A71_R9-en.pdf